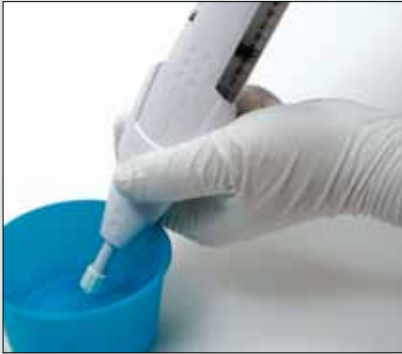


FemVue Sono HSG: Procedure Guide



FemVue Preparation:

1. Completely submerge tip into a saline-filled bowl.
2. Fully pull back the plunger handle and hold until the saline chamber completely fills. Do not squeeze the air and saline chambers.

*femVue*TM
Saline-Air Device

FemVue Sono HSG Procedure:

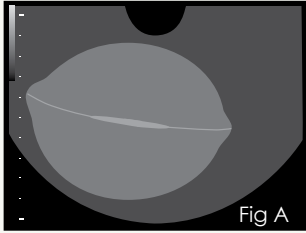


Fig A

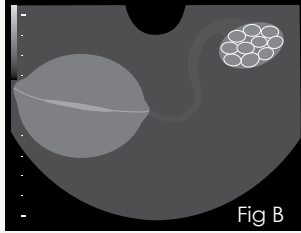
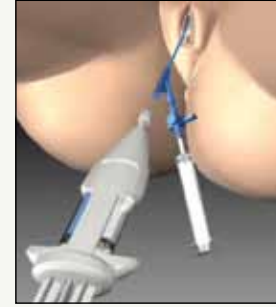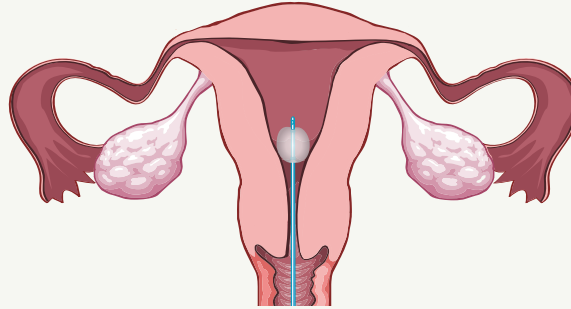


Fig B



1. Sonographic Landmarking

Conduct your standard ultrasound evaluation per your practice guidelines.

Attempt to locate the following in the **transverse view**:

- **Endometrial stripe and uterotubal junctions** (Fig A)
- **Position of each ovary relative to the uterus** (Fig B)

2. Insert Catheter

Insert the catheter per the catheter's Instructions for Use.

If desired, first perform SIS with a saline-filled syringe per your practice protocol, because bubbles in the uterus from the FemVue may cause artifact.

3. Inflate Balloon*

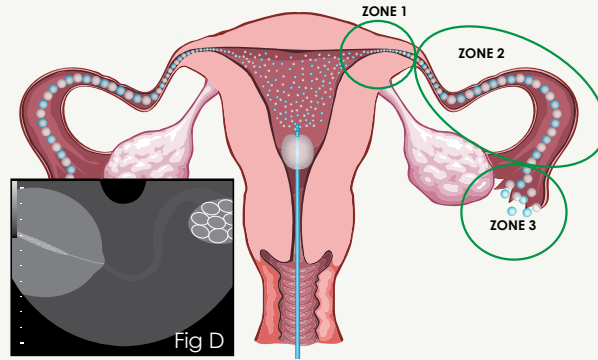
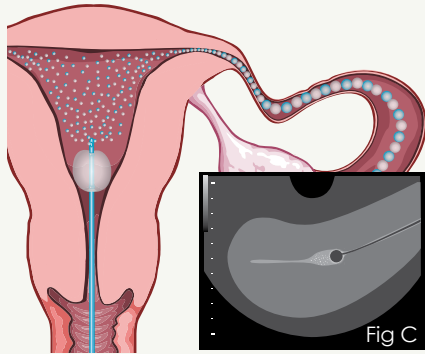
Inflation of the balloon with subsequent placement over the internal cervical os is recommended to prevent retrograde flow.

*If applicable.

4. Prime and Connect

To prime FemVue, submerge the tip in the saline-filled bowl and depress the plunger handle until bubbles are visible.

Ensure FemVue is primed just before attachment to avoid delay in contrast visualization.



- Zone 1:** Flow seen in the uterotubal junction
- Zone 2:** Flow through the tube (may or may not be seen)
- Zone 3:** Flow around the ovary; bubbles in the cul-de-sac; fimbrial disturbance

5. Deliver Contrast Slowly

With ultrasound probe in place, slowly and steadily depress the plunger handle to deliver the contrast. Visualize saline-air contrast (bubbles) entering the cavity (distention is not necessary).

Confirm in the **sagittal view** there is no retrograde flow through the cervix. If needed, adjust the balloon's placement or use a balloon to block the flow. (Fig C)

Start with one fill of the FemVue Saline-Air Device. Use minimum number of fills necessary. Do not exceed six (6) filled syringe volumes.

6. Make Tubal Assessment

In the **transverse view** orient the probe to observe the uterotubal junction to assess contrast flow in one tube. Although flow may be seen bilaterally, evaluate each tube individually. (Fig D)

- Locate flow in Zone 1 and hold view to observe.
- Slowly and methodically scan to possibly observe tubal flow in the remaining zones.

Evaluate contralateral tube.

Demonstrating tubal patency

Guidelines from historical literature using saline and air:

- **Flow in the interstitial part of the tube** (minimum criterion).^{1,2}
- **Flow throughout course of tube.**¹
- **Bubbles seen around ovary or in cul-de-sac.**^{1,2}
Fimbrial turbulence.³

Troubleshooting:

No contrast exiting catheter and plunger resistance

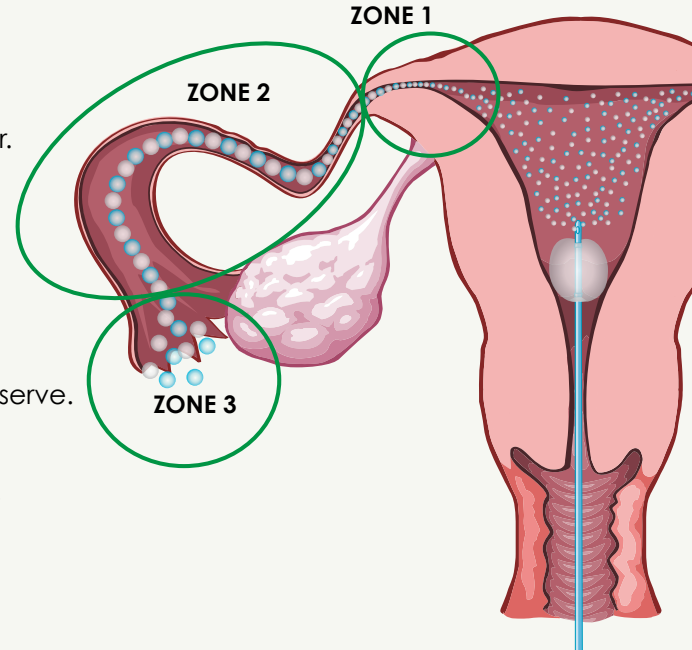
- Make certain that catheter clamp is open, if applicable.
- Confirm the catheter is patent.
- Ensure FemVue has not been over tightened to catheter luer.
- Replace catheter if kinking is suspected.

No contrast flow visible in Zone 1

- Ensure there is no retrograde flow through the cervix.
- Consider repositioning ultrasound probe.
- Hold probe, maintain plunger handle position, and wait for resolution of possible tubal spasm.
- After extensive observation, trace laterally to Zone 3 and observe.

Inadequate visualization of tube

- Consider pulling back with probe if tube is viewed anteriorly.
- Consider adjusting ultrasound equipment settings.



References:

- ¹ Volpi, Ultrasound Obstetrics Gynecology. 1996;7:43-48.
- ² Exacoustos, The Journal of the American Association of Gynecologic Laparoscopists. 2003;10(3):367-372.
- ³ Allahbadia, Fertility and Sterility. 1992;58(5):901-907.

For more information contact Femasys Customer Service at 1.877.336.2562 or visit us at www.FemVue.com

Distributed by



 femasys[®] Innovations for Women

© 2011 Femasys Inc.
All rights reserved. 03153:03 05.Aug.2011